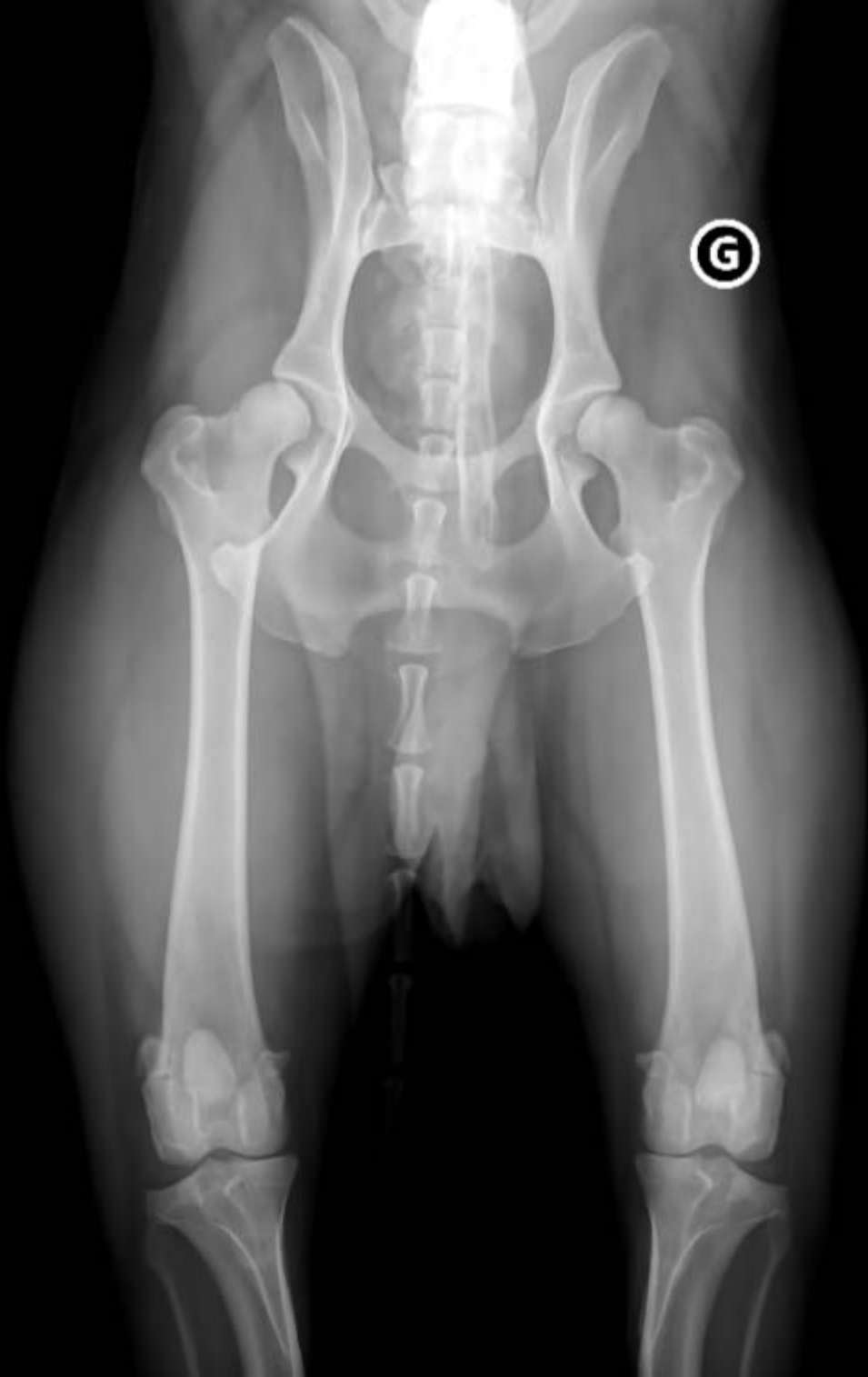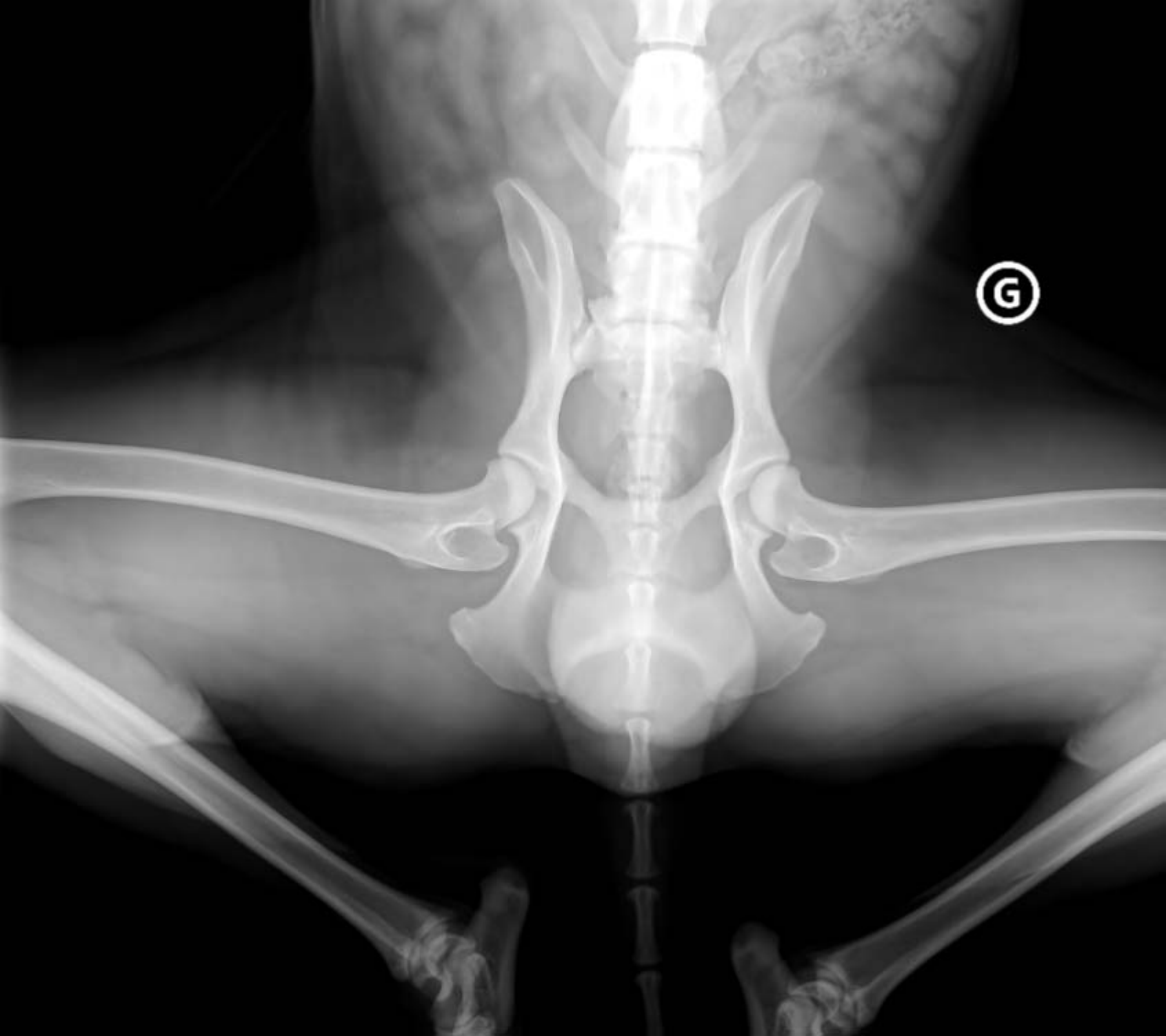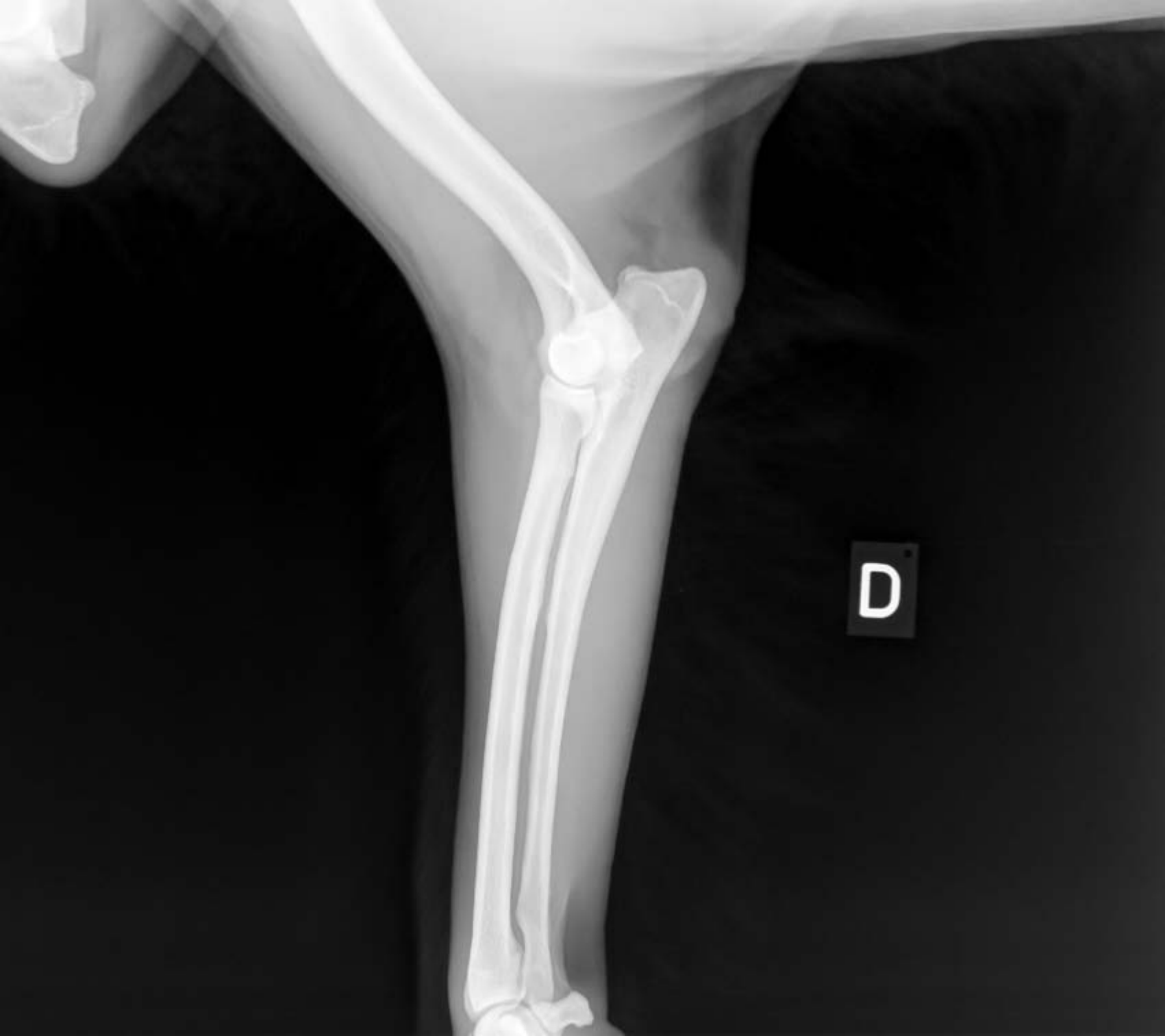






G

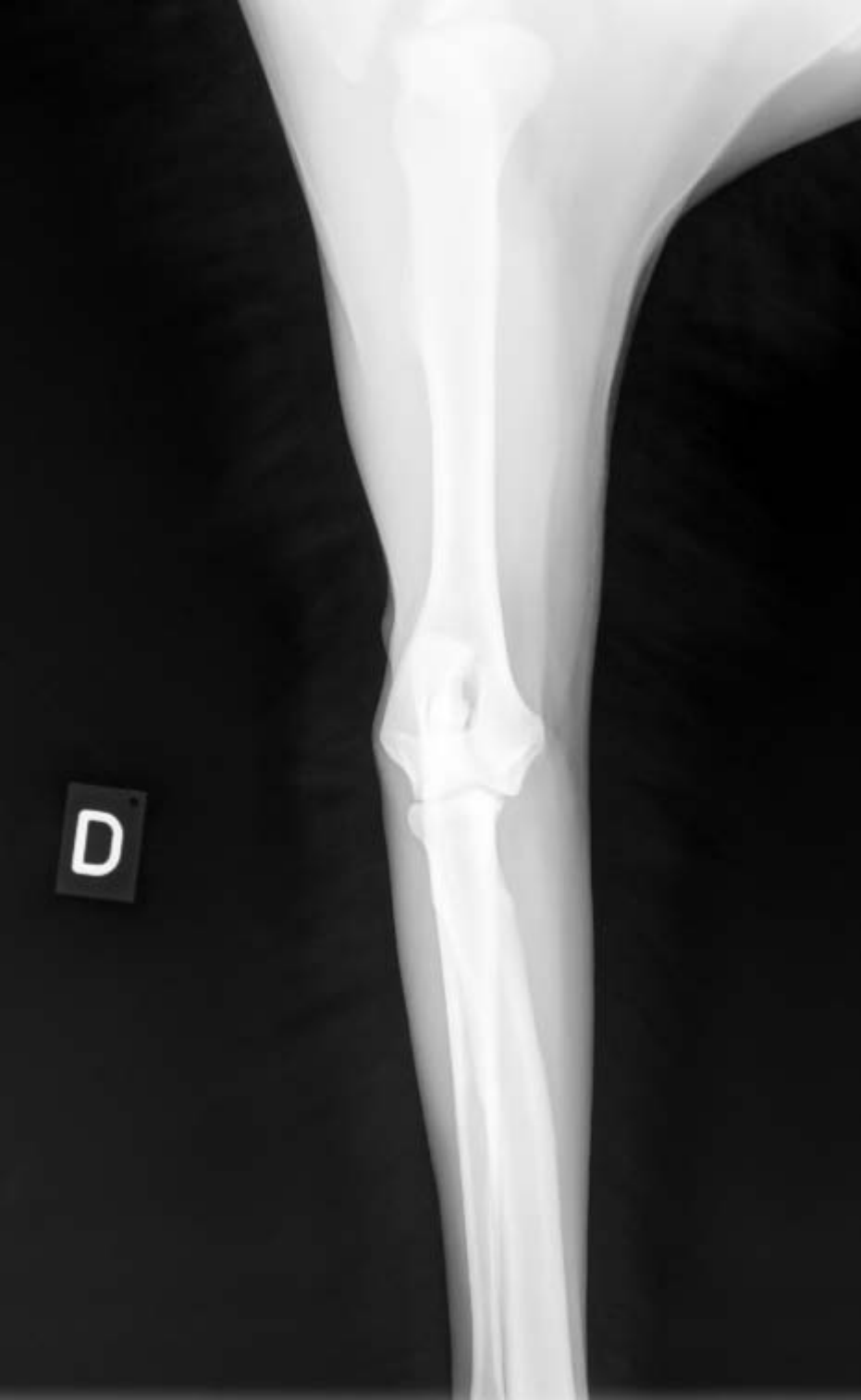

D

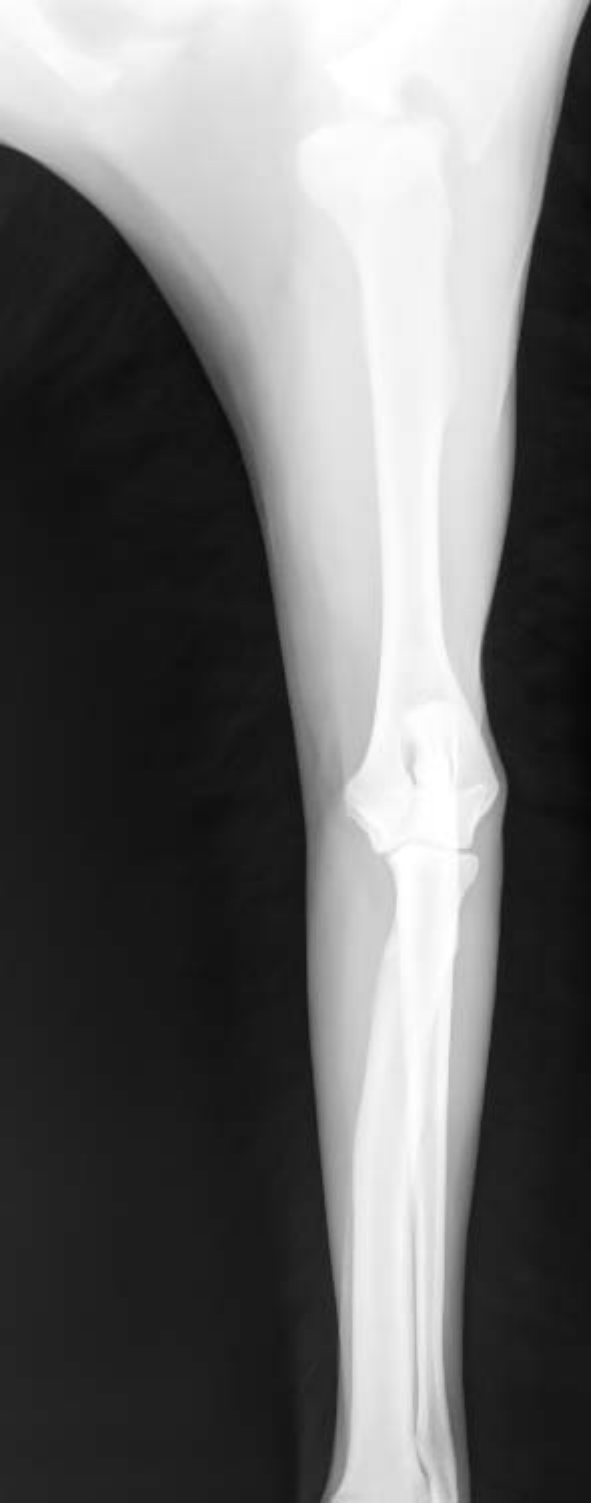

A lateral radiograph of a horse's knee joint. The image shows the distal femur at the top, the patella in the middle, and the tibia below. A prominent, circular, radiopaque object is visible in the joint space, likely a marker or a foreign body. A small black square with the white letter 'G' is located in the lower-left quadrant of the image.

G



D



e